

today's



chiropractic®

READ BY CHIROPRACTORS AROUND THE WORLD

January/February, 1988

THE MAGAZINE THAT REFLECTS THE LIFE PRINCIPLE IN CHIROPRACTIC

(26) P. 95
The Atlas Sagittal Plane



**Stop Your
Patient Base
From Shrinking!**

**What Are
The Right
Questions,
When Shopping
For Software?**

**Why Did The
Moscow Ballet
Suddenly Turn
To Chiropractic?**

**We Must
Define
What Is
Considered
"Chiropractic
Pediatrics".**

Vadim Pisarev, Marina Bogadanova
Perform "Diane And Acteon".

The Atlas Sagittal Plane

By Roy W. Sweat, D.C.

The atlas sagittal plane is constructed from the sagittal cervical x-ray (Fig. 1). The atlas sagittal plane (ASP) is necessary to establish so that the atlas frontal plane x-ray is taken to observe the atlas at a direct frontal plane view. On the frontal plane, we do not want to look at the atlas from a superior or inferior view.

In the atlas orthogonal program, we take the sagittal x-ray view first and establish the ASP line and then we take the frontal plane x-ray.

Using a Coordinate System

White and Punjabi, in their book *Clinical Biomechanics of the Spine*, recommend that a three-dimensional coordinate system be used to document the complete mechanical behavior of spinal motion segments and functional biomechanics of the spine. They recommend the right-handed Cartesian orthogonal coordinate system.

"The suggested central coordinate system with its origin between the

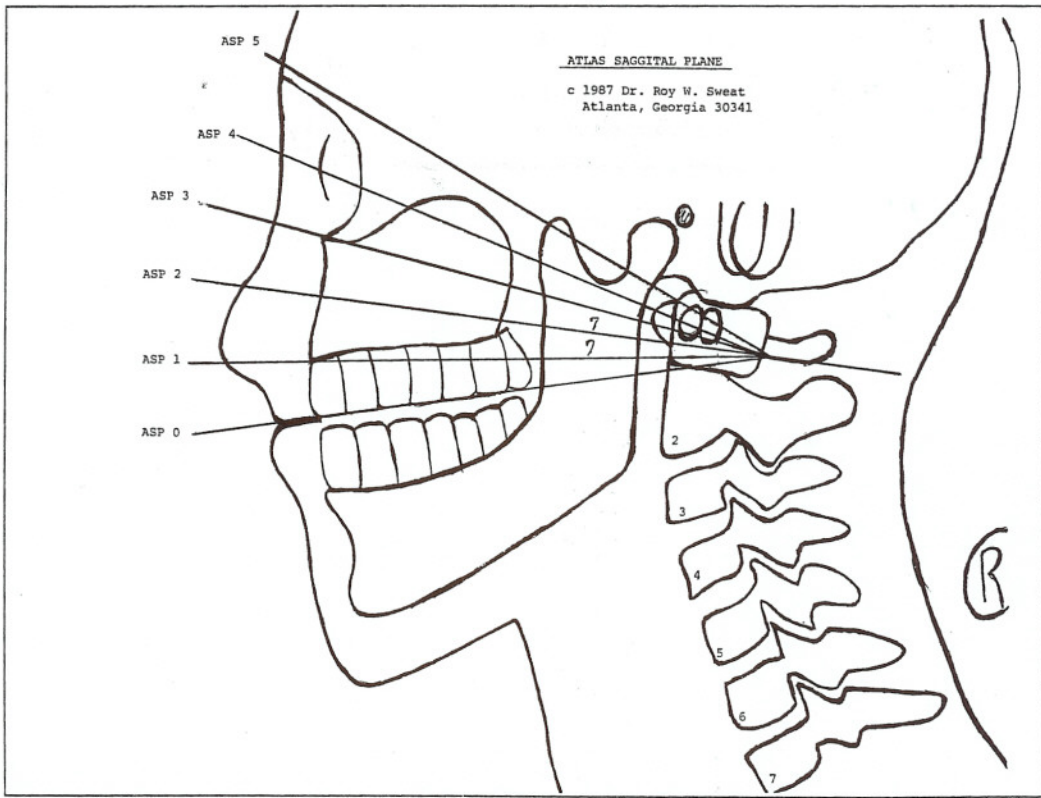
cornua of the sacrum is shown. Its orientation is as follows: The -y-axis is described by the plumb line dropped from the origin, and the +x-axis points to the left at a 90-degree angle to the y-axis. The +z-axis points forward at a 90-degree angle to both the y-axis and the x-axis. The human body is shown in

relation to the origin of the coordinate system. The arrows indicate the positive direction of each axis. The origin is the zero point, and the direction opposite to the arrows is negative." (Fig. 2)

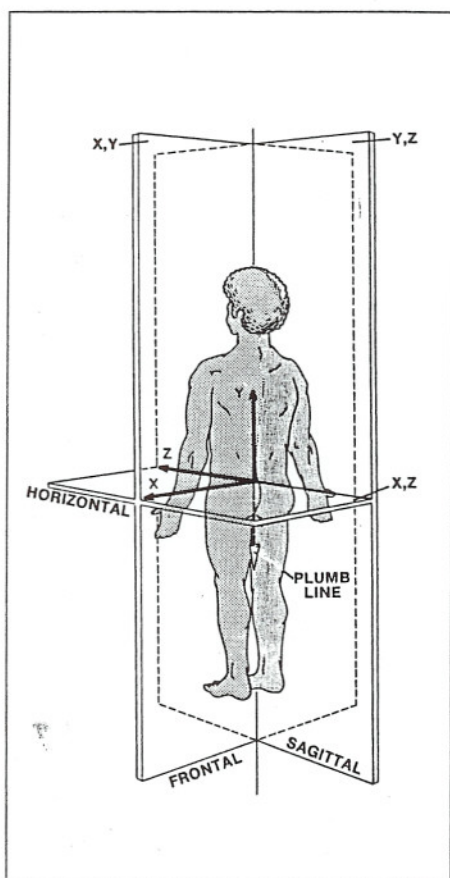
Constructing the ASP Line

We mark the inferior border of the posterior arch where it joins the atlas lateral mass as our first landmark. We then move posteriorly along the inferior border of the posterior arch for one-quarter to one-half inch and put a second marking. We then construct our ASP line through these two points extended to the anterior facial features. All ASP lines 0 or lower should be taken as A-P open-mouth views.

There are three growth centers in the atlas, one in each lateral mass and one in the anterior arch. On the frontal x-ray, the inferior border of the posterior arch will be horizontal and in the center of the lateral masses. Each ASP



the anatomic position. There are some basic conventions that are observed which make this a useful system. The planes are as shown: The sagittal plane is the y,z plane; the frontal plane is the y,x plane; and the horizontal plane is the x,z plane. Movements are described



line will average seven degrees. We find that 90 percent of the ASP lines will be 1, 2, and 3.

About the author: Roy W. Sweat, D.C., is a noted author, lecturer, and researcher who maintains a private practice. For further information, write to him at 3274 Buckeye Road, N.E., Atlanta, Georgia 30341.

References

1. White and Punjabi, *Clinical Biomechanics of the Spine*, (Reprinted with permission), Lippincott, 1978, p. 62.
2. Warwick and Williams, *Gray's Anatomy*, 35th ed., p. 246, W.B. Saunders Co., 1973.
3. Case Studies, Sweat Chiropractic Clinic.