

# Atlas Orthogonality

by Roy W. Sweat, D.C., B.C.A.O.

Matthew H. Sweat, B.A., D.C., B.C.A.O.

Richard E. Kersey, D.C., B.C.A.O.

David A. Nygaard, M.S., M.B.A., D.C. Candidate.



CHIROPRACTIC  
*Techniques*

**A**tlas Orthogonality is a Chiropractic program to find and correct spinal subluxations based on scientific and biomechanical procedures. They submit to the scientific community the neutral relationship of the cranium-atlas-axis-cervical spine. ORTHOGONALITY (N) – the quality or state of being orthogonal. ORTHOGONAL (ADJ) – having to do with or involving right angles, intersecting at right angles, mutually perpendicular. ORTHOGONIST (N) – certified doctor of Chiropractic orthogonality.

## The Human Body Is A Vertical Structure

The human body is a biped and maintains a center of gravity in the middle of its two pedal supports. When the body leaves its vertical center there is always an adaptation and a compensatory shifting of the lower structures to maintain a position as near vertical as possible. As the head leaves vertical and moves horizontally, there is a compensatory shifting of the vertical spine laterally to maintain a center of gravity that

is continued all the way through the entire spine. When a person has a scoliosis, curvature, low shoulder, high hip, or any body imbalance, innate intelligence keeps the body as vertical as possible by shifting the entire structure to maintain a center of gravity. In abnormal or congenital conditions where one occipital condyle is higher, than the other, innate always tries to adapt by having one lateral mass wider than the other, or one side of the axis body higher than the other side to keep the body balanced as vertical as possible. In our orthogonal adjusting procedure we are always trying to make the head vertical, the atlas level, and the cervical spine vertical.


## Review Of Literature

The articulations of the spine include the three major types of joints: synarthroses, diarthroses and amphiarthroses. The Occipital-Atlanto-Axial Complex is a diarthrodial – synovial joint, or a “freely moveable joint.” Dr. John F. Grostic stated in his seminars in Ann Arbor, Michigan, “The atlas area has the most wedges, circles, incline planes, fulcrums, and levers than any other area of the spine.” Dr. Ruth Jackson in her book on the cervical syndrome states, “The Cervical spine is more subject to injury than any other area of the spine.” Gray’s Anatomy states, “The cervical spine has more range of motion than any other area of the spine.” Dr. Gillet of Belgium states, “It is fast becoming recognized that the most important region in the spine, the region in which subluxations are the most pathogenic, is the cervical region.” Dr. B.J. Palmer’s famous “hole-in-one” atlas procedure states, “There are no interosseous locks in the atlas articulations and everything is from above down and inside out.” White and Panjabi states, “The extensive amount (47 de-


grees) of axial (y-axis) rotation at C1-C2 can sometimes cause clinical problems with the vertebral arteries. Symptoms of vertigo, nausea, tinnitis, and visual disturbances may occur from occlusion of the vertebral artery associated with axial rotation of the atlas.” Rothman and Simone state, “40 percent of flexion and extension in the cervical spine is at the occipito-cervical joint.” There are eight external craniocervical ligaments and five internal craniocervical ligaments. We have the deep muscles of both the anterior cervical spine and the posterior cervical spine. We then have six pairs of small muscles that connect the occipital bone, the atlas, and the axis. There are three pairs of superficial and lateral cervical muscles.

## Guidelines for Pre-Adjustment and Post-Adjustment Radiographs

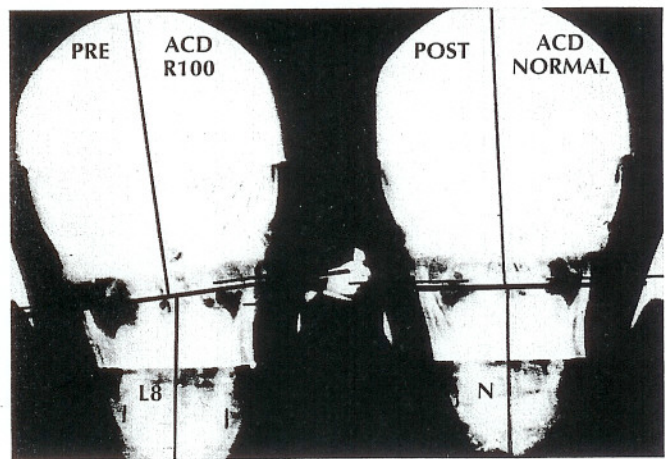
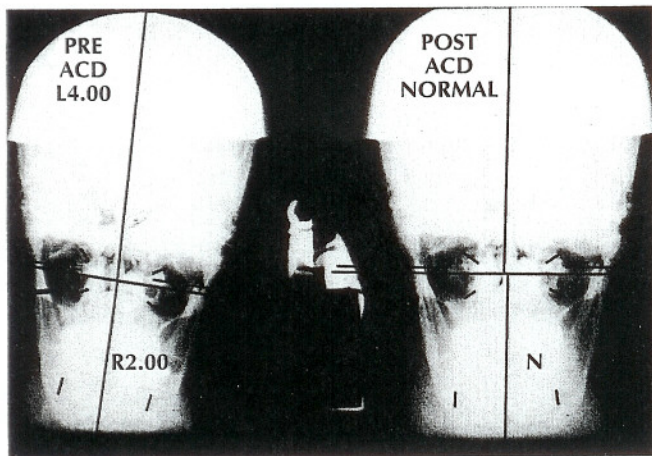
Pre-adjustment and post-adjustment x-rays have been important standards of care in the Chiropractic profession for 49 years. In the Atlas Orthogonal programs, the patient must have three pre-adjustment cervical x-rays and two post-adjustment x-rays taken immediately after the first adjustment in the cervical area. When there are other areas of the body involved, they must be x-rayed, prior to the adjustment, in addition to the five cervical x-rays. Pre x-rays are a vital part of the Chiropractic examination. Post x-



Full-view Atlas Orthogonal Adjusting Instrument



Close-up Atlas Orthogonal Adjusting Instrument



rays are important to document the efficacy of the Chiropractic care plan.

### Standard Of Care

There are five categories used in the standard of care for the Atlas Orthogonal Chiropractic Procedures: Phase one is Acute with a care plan time of 1-10 times for, a period of 1-2 weeks. Phase Two is Sub-Acute with a care plan time of 2-3 times a week for a period of 2-3 months. Phase Three is Chronic with a care plan time of once a month for an indefinite period of time. Phase Four is supportive with a care plan time of 3-6 times a year; 2-3 times each episode then dismissed. Phase Five is Rehabilitative with a care plan time of twice a month for 1-3 months.

### Atlas Orthogonal Percussion Adjusting Instrument

The first instrument we made had settings varying from one-sixteenth inch to one-half inch depth thrust. The second series of instruments had one-sixteenth inch to one-quarter inch depth thrust. The third series of instruments we made had settings varying from one-eighth inch to one millimeter depth thrust, which was an additional 50 percent less depth thrust than the previous one. The newest series of instruments we have made is a percussion instrument with zero excursion. The first percussion instrument had a 15 pound solenoid which rendered 8 to 15 pounds of thrust. The second series we used a 6 pound solenoid which produced a 6 to 10 pound of thrust. The latest solenoid is 1.8 pounds which produces 3 to 6 pounds of thrust. The following statement is from Dr. Eugene T. Patronis, Jr., Ph.D., School of Physics, Georgia Institute of Technol-

ogy, after examining the percussion instrument, "I would describe the operation of your device as follows: A mechanical impulse is imparted to a metal stylus by means of a spring loaded plunger. The strength of this impulse is determined by the initial degree of compression given to the plunger spring. The impulse imparted to the stylus by the plunger excites a compressional wave in the stylus. The velocity of this wave in the stylus material is determined by the square root of the ratio of the Young's modulus to the density of the stylus material. At the patient-stylus interface, dependent on the impedance match, a portion of the wave energy is transmitted into the patient and a portion is reflected back to the plunger."

### Adjusting Vertebral Subluxation Within Their Normal Range Of Motion

A subluxation is viewed as a consistent relative misalignment within the normal range of motion of the vertebrae. The normal range of motion between the atlas and the occipital condyles is only approximately five degrees, without abnormalities. Converting five degrees to lineal measurement on a three-inch diameter circle is  $\frac{1}{8}$  inch or 3.18 millimeters.

### Light Is Right

Currently most doctors using the hand held instrument set the instrument at its lowest possible depth thrust. The lighter the thrust utilized the better the atlas will move within its articular beds. We have found that post x-rays validate the lighter forces resulting in better reductions. We are fortunate that light force adjusting protocol utilizing minimal depth provides the most favorable re-

sults. We strongly believe it is not necessary to be forceful to properly move the atlas. The lighter or shorter the adjustment thrust can be performed, the better the results will be in the structural changes in the atlas and cervical area.

### Conclusion

There is more than one way to adjust an atlas. In our opinion the Atlas Orthogonal Adjusting Program is the most precise and the most reproducible of all Chiropractic adjusting programs. Minimal depth, low forces and specific angles of correction are appropriate in adjusting the atlas. The most effective Chiropractic technique will be the one that can produce the fastest, most effective results, last the longest, be rendered at a reasonable cost and ensure the least amount of risk. ■

### References

- Palmer School of Chiropractic 1991 Announcement, Davenport, Iowa: Palmer School of Chiropractic, 1991. p. 217.
- Palmer School of Chiropractic, 1947.
- Grostick, John F., Grostick Seminars, Ann Arbor, Michigan, 1946.
- American Medical Association, "Guides to the evaluation of Permanent Impairment", 2nd Ed., p. 47.
- Sweat, R.W., Atlas Orthogonal Seminars, Atlanta, Ga., 1980.
- Pre and Post X-rays performed with the Atlas Orthogonal X-ray equipment.
- OUM, Olympic Underwriting Managers Group, Bellevue, Wash.
- "Guidelines for Pre and Post Radiographs for Care Documentation," Today's Chiropractic, March/April 1995, pp. 58-61.
- Dorland's Illustrated Medical Dictionary, 27th Edition, 1988, p. 1405.
- Macnab, Ian, Panjabi, Manohar, and White, Augustus A., D., Clinical Biomechanics of the Spine, 1978, p. xi.