
CASE STUDY

Upper Cervical Chiropractic Care of a Patient with Post Concussion Syndrome, Positional Vertigo, and Headaches

Alisha Mayheu DC¹ & Matthew Sweat DC²

ABSTRACT

Objective: To outline clinical changes after chiropractic care in a patient with vertigo, headaches, and post concussion syndrome.

Clinical Features: A 23-year-old female presented for chiropractic care five months after a slip and fall that resulted in a concussion. The patient presented with symptoms of vertigo and headaches consistent with post concussion syndrome. The patient had a longstanding history of headaches that were exacerbated by the concussion and a new complaint of positional vertigo that occurred immediately following the trauma. Radiographs ruled out fracture but were remarkable for upper cervical subluxation.

Intervention and Outcomes: The patient received upper cervical specific chiropractic care through the technique of Atlas Orthogonal Chiropractic. Atlas Orthogonal protocol of upper cervical palpatory scanning and supine leg length analysis were used to indicate when an upper cervical adjustment was to be administered. Radiographic analysis was used to determine the misalignment and the exact vectors of the upper cervical adjustment.

Conclusions: Clinical findings suggest that upper cervical vectored manipulation was beneficial in this patient with vertigo, headaches, and post concussion syndrome.

Key Words: *Post Concussion Syndrome, Headache, Vertigo, Chiropractic, Upper Cervical Chiropractic, Vertebral subluxation.*

Introduction

The human brain with all of its complexities is a subject that science has yet to fully understand. One such complexity is the effects that occur after mild traumatic brain injury and concussion. Concussion is one of the most common forms of neurological injury seen throughout the world.¹

During the 2001 meeting of the First International Symposium on Concussion in Sport, concussion was stated to “occur as the

result of a direct blow to the head, face, neck, or elsewhere in the body with impulsive forces transmitted to the head...and may or may not involve loss of consciousness, as less than 10% of concussions result in loss of consciousness.”^{2,3} There is some controversy surrounding the exact underlying mechanism of concussion. Patients with concussions often have normal MRI scans making it difficult to ascertain the deformation that occurs in the brain after a concussion. Even in cases where brain compression is evident on MRI, there are no objective tools to directly measure this brain deformity.⁴

-
1. Private Practice of Chiropractic, Greensboro, GA
 2. Private Practice of Chiropractic, Atlanta, GA

A lack of objective measurement tools has led to more hypotheses and less consensus among members of the medical and research community. One thing that is for certain is the fact that some patients continue to be plagued by symptoms even years after a concussion. This prolonged symptom presentation after a concussion is termed *post concussion syndrome*.

Post concussion syndrome or PCS is a varied collection of symptoms that can occur for weeks to months, even years after a concussion. This means that beyond the immediate effects of a concussion, a health care provider must also consider the symptoms experienced in post concussion syndrome. Its symptoms, which often follow uncomplicated mild head injury, commonly include headache, dizziness, fatigue, poor memory, poor concentration, irritability, depression, sleep disturbance, frustration, restlessness, sensitivity to noise, blurred vision, double vision, photophobia, nausea, and tinnitus.⁵ Some of these symptoms such as headache can prove to be a chronic problem for patients with PCS.

It is reported that of patients with PCS, 89% experience chronic headache.⁶ The prolonged presentation of this symptom can prove to be quite a strain on the patient and even to society. It has been reported that every day in the USA approximately 300,000 individuals stay in bed because of headaches.⁷ This obviously results in strain to the headache sufferer as well as the economy due to labor and workforce losses. This makes it all the more important to find effective ways to treat the chronic pain sufferers of PCS. The complaint of vertigo only further complicates these cases.

Vertigo is reported by Ponka as “a subjective impression of movement of oneself or ones environment” and accounts for one of the top ten most commonly diagnosed issues in family practice.⁸ Vertigo can be an unsettling condition for a patient to experience and can lead to a feeling of lack of control. This uneasy feeling of spinning can lead to complications with ambulation and could even result in falls and subsequent head traumas, which could further compromise the concussion patient. Research indicates that subsequent concussions result in compounding issues.

Harmon reports that “there is evidence that repeated concussions can result in cumulative neurological damage, even when the injuries are separated by months or years.”³ It becomes apparent that interventions to address the symptoms of PCS are necessary to not only improve the quality of life for the patient but to also prevent further harm to the patient. Chiropractic seems well positioned to address these symptoms of PCS.

Chiropractic care has proven to be beneficial in treating some patients with symptoms associated with PCS such as headaches and vertigo. Vernon proposed that cervical spine involvement is far more relevant to the origin of all headache categories than previously documented; and this proposal was supported in research of a chronic headache patient by Tuchin, et al.⁹ Further research indicates that chiropractic care is also beneficial in addressing the symptoms of vertigo. Kessinger notes that chiropractic care improves cervical spine function, with its neurological and vascular components, which improves and ameliorates symptoms of vertigo.¹⁰

Case Report

History

A 23-year-old female with symptoms of vertigo and chronic headaches associated with Post Concussion Syndrome presented for chiropractic care. Although the patient had a longstanding history of headaches, the patient had experienced an intensification of her symptoms following a head trauma five months prior to presenting for care. The head trauma was reported as a slip and fall from a height of two feet in her bedroom, which resulted in direct impact of the left lateral aspect of the cranium. On the day of the trauma, the patient was treated by the ER and was diagnosed with a concussion. She presented to the ER with symptoms of nausea, vertigo, a bilateral throbbing pain in the cervical spine, and an intense headache. She reported that her headache at that time was rated as 9/10 as determined by the visual analogue scale (where 0 = No Pain, 10 = The Worst Pain of One's Life). She was examined and released the same day and did not receive any treatment or medications. It should be noted that only a small proportion of patients that present to the ER following mild brain trauma are admitted, and those admitted are patients at risk for intracranial hemorrhage.¹¹

The symptom of vertigo started immediately after the trauma. The vertigo was described as a positional vertigo that occurred when going from sitting to standing. She reported that the symptom of vertigo and intense headaches had interfered with her activities of daily living (ADL's) for the past five months. She was unable to exercise or properly concentrate during classes. She also reported symptoms of fatigue, irritability, insomnia, memory problems, and problems with concentration that began immediately following the trauma and lasted for two weeks. She reported a 10 year history of constant, daily bilateral temporal-occipital headaches that were rated as 5/10. In the five months following the concussion, the intensity of headaches had increased to 9/10.

Chiropractic Examination

On examination, Maximum Cervical Compression and Jackson Compression were both positive bilaterally. Cervical ranges of motion were tested and revealed pain upon both left and right lateral flexion. Musculoskeletal palpation revealed trigger points in the upper, middle, and lower trapezium fibers bilaterally. Cervical scanning palpation as per Atlas Orthogonal (AO) protocol resulted in a grade 3 scan in this patient bilaterally from C1 to C3. AO scanning palpation is described as “a manual, tactile, cervical spine examination for objective findings such as muscular spasms, muscular contractions, edematous swelling, or osseous protuberances. The subjective findings of the scan are extreme tenderness, pain, hypersensitivity, hyperirritability, and neurological insult in the positive palpated areas.”¹² Grades are used from 1-3 to indicate severity and are noted as: grade 1 mild, grade 2 moderate, and grade 3 severe. A grade two or three scan is typically found in conjunction with a short leg and indicates the need for an adjustment.¹² The patient was placed in the supine position to rest for ten minutes. Then the supine leg length analysis was performed using a leg-check grid¹² (Figure 1), which resulted in right short leg of 1 inch. Special care was taken so as not to manually remove inversion/eversion,

internal/external rotation, and/or plantar-flexion/dorsi-flexion so that the legs were measured in their neutral position.¹² After the AO adjustment, the patient was again reassessed with scanning palpation and supine leg length analysis.

Radiographic Imaging

Radiographic imaging of neutral sagittal, frontal, horizontal, AP open mouth, AP lower cervical, and vertex views were obtained before chiropractic care was administered. All views were taken with the patient in an adjustable chair in a seated neutral posture with the hard palate level with the floor and head clamps were used on all views. Seated neutral posture means that no external forces were placed on the patient's head to compensate for postural distortions. All views were taken on 24x30 cm film at 46 inches SID. The primary views used in setting the coordinates and angles of the adjustment in the Atlas Orthogonal Instrument are the Sagittal, Frontal, and Horizontal views. Therefore, these are the views that will be discussed in this case. The sagittal view was taken and analyzed before all other views were taken. According to Atlas Orthogonal protocol, the Atlas Sagittal Plane (ASP) line (Figure 2) must first be determined on the sagittal radiograph in order to determine proper tube angle and proper placement of the central ray through the atlas.¹² The remaining views were then taken following the analysis of the sagittal view. Comparative radiographs were then taken immediately following the initial upper cervical adjustment to determine the accuracy of the correction vectors and the effectiveness of the adjustment.¹²

Radiographic analysis of the films was performed with digital computer software and revealed the following findings:

The Sagittal View

On the sagittal view one line of mensuration was constructed, the Atlas Sagittal Plane line, or ASP. In this case the pre adjustment analysis showed an ASP 2 (+15). The post adjustment sagittal view showed an ASP 2 (+13).

The Frontal View

On the frontal view three lines of mensuration were drawn, one through the center of the atlas giving the Atlas Frontal Plane Line (AFPL), one through the center of the cranium giving the Frontal Cephalic Line (FCL), and one through the center of the cervical spine giving the Cervical Spine Line (CSL). This view is also used to measure condylar and axial circles as well as axis spinous rotation, or AXSP.¹² In addition, there are four angles derived from this film: the Atlas Frontal Plane Line Angle (AFP), the Atlas Cephalic Displacement Angle (ACD), the Cervical Spine Angle (CS), and the Circle Tangent Angle (C/A). These angles are used to determine the subluxation complex in the frontal plane around the z-axis to determine the Z-factors which are factors of coordinates set in the Atlas Orthogonal instrument for the correction of the subluxation in the z-axis. The Y-Factors for the adjustment will be determined from the horizontal view. In this case, the pre adjustment frontal film (Figure 3) showed AFP high 3 degrees, CS right 3.25 degrees, ACD left 1.25 degrees, CS right 3.25 degrees, C/A of 8 degrees, and AXSP left 9 degrees. Analysis of the post adjustment Frontal view

(Figure 4) demonstrated the following: AFP 0 degrees, CS 0 degrees, ACD right 0.75 degrees, CS 0 degrees, C/A of 13 degrees, and AXSP left 4 degrees.

The Horizontal View

On the horizontal view, two lines of mensuration were drawn, one through the superior posterior edges of the lateral masses and one through the center of the cranium.¹² From these lines, the Atlas Horizontal Rotation (AHRy) is determined which represents the extent of atlas subluxation in the y axis.¹² This will determine the Y-Factor for the coordinates set in the Atlas Orthogonal instrument for the correction of the subluxation in the y-axis. In this case, the pre adjustment AHRy was anterior 0.25 degrees. Analysis of the post adjustment Horizontal View demonstrated AHRy was anterior 0.15 degrees.

Chiropractic Care

After the initial examination and x-rays were performed, the patient was positioned with proper mastoid process support in a side-lying posture based on findings during the radiographic analysis.¹² The patient was adjusted using the Atlas Orthogonal instrument which delivers a specific vectored low force, low velocity impulse to the atlas vertebra based on coordinates derived from radiographic analysis. Immediately after the adjustment, post x-rays were taken to evaluate the effectiveness of the adjustment. The patient was also re-evaluated using the cervical scanning palpation and leg length analysis.

Improvements were noted in x-ray analysis and cervical spine scanning palpation. Supine leg length analysis revealed that the legs were balanced immediately after the adjustment. Subjective findings of resolution of headache and vertigo were noted immediately following the adjustment. Examination the following day revealed a grade 1 on cervical scanning palpation and the legs were balanced in the supine leg length analysis. It was determined that there was no need for further adjustment to the cervical spine at that time.

The patient's third visit was one week following the first adjustment and revealed that the patient was still balanced and was holding her adjustment. At that time, she reported that she had not experienced any headaches or vertigo since receiving her first AO adjustment one week prior. The patient's fourth visit was two weeks following the first adjustment and at that time the patient reported a slight nagging headache had begun earlier that day, rated at 2/10, but she did not have any symptoms of vertigo. She reported that the exacerbation could be due to increased studying frequency with prolonged sitting and the coincidental event of misplacing her reading glasses.

The patient's care was continued on a frequency of twice per month for evaluations and progress monitoring. She was evaluated with AO protocol for necessity of adjustment and her symptoms were monitored at every evaluation. She continued to report a complete resolution of vertigo and intermittent headaches rated as 2/10 that occurred at an average of two hours/day.

Discussion

The patient in this case presented with symptoms consistent with post concussion syndrome or PCS. She had complaints of intense constant daily headaches and positional vertigo following a diagnosis of concussion. These symptoms had interfered with her life and ADL's daily for the five months following head trauma. There is evidence that up to one in twenty adults experience symptoms of headaches nearly every day or every other day.¹³ It is clear that the prevalence of the symptoms surrounding PCS cannot be ignored. In order to properly address these symptoms, the pathophysiology of concussion and post concussion syndrome must be understood.

The upper cervical spine seems to be an important area of consideration when addressing the pathophysiology involved in patients with chronic symptoms of vertigo and headaches following a concussion. One theory suggests that the likely entity of concussion reflects functional membrane dysfunction with the bulk of anatomical focus in the brain stem.¹ This would place a great deal of significance on a treatment such as the upper cervical specific technique of Atlas Orthogonal due to the anatomical proximity of the atlas to the brainstem. There is some indication that misalignment of the atlas can compromise canal space which could jeopardize the function of the medulla; and the cord at the cranio-vertebral junction may be influenced by biomechanical alterations in the upper spine.¹⁰ This could result in the symptoms reported in this case.

When considering the pathophysiology related to vertigo, the upper cervical spine again seems to be an important area. Vertigo is the sensation or illusion of movement. Vertigo results from acute unilateral vestibular lesions that can be peripheral such as labyrinth and vestibular nerve or central such as brainstem and cerebellum.¹⁴ It is reported that 44% to 65% of patients with a diagnosis of vertigo involve the peripheral type lesion leaving 35% to 56% to the central lesion.¹⁵ One proposed theory suggests that misaligned vertebrae of the upper cervical spine could create stress on the vertebral artery resulting in decreased blood flow to the brain and brainstem which could adversely affect vestibular centers, resulting in vertigo.¹⁰ This could explain the symptoms of post concussion vertigo presented in this case.

The upper cervical spine is also an important area of discussion when considering headache associated with PCS. One hypothesis regarding this is that the cervical myodural bridge could possibly be the underlying cause of some types of headaches. It is postulated that "exertion through the myodural bridge may exert tension through the pain sensitive dura; and chiropractic adjustive procedures likely prove beneficial through this anatomic relationship."¹⁶ This anatomical relationship could explain the symptoms of post concussion headache presented in this case.

Conclusion

This paper presented a patient with a five month history of symptoms of headache and vertigo associated with Post Concussion Syndrome, PCS. This case may serve to demonstrate the benefits of specific, vectored, upper cervical

chiropractic care in the care of patients with these symptoms associated with PCS. To confirm that positive outcomes obtained in this case could be replicated, more extensive studies are indicated. Further investigation of concussion, upper cervical injury, and the resulting pathophysiology associated with PCS should also be pursued.

References

1. McCrory P. The Nature of Concussion: a Speculative Hypothesis. *Br J Sports Med* 2001;35:146-47.
2. Carson J., Tator C., Johnston K., Kissick J., Purcell L., Hunt B. New Guidelines for Concussion Management. *Can Fam Physician* 2006; June:52:756-57.
3. Harmon K. Assessment and Management of Concussion in Sports. *Am Fam Physician* 1999; Sept: 60:887-94.
4. Bayly P., Cohen T., Leister E., Ajo D., Leuthardt E., Genin G. Deformation of the Human Brain Induced by Mild Acceleration. *J Neurotrauma* 2005; Aug: 22(8): 845-56.
5. King N. Post Concussion Syndrome: Clarity Amid the Controversy? *Br J Psychiatry* 2003; 183:276-78.
6. Uomoto J., Esselman P., Cardenas D. Treatment of Post Concussion Syndrome. *West J Med* 1992; Dec: 157(6): 665.
7. Stovner L., Andree C. Impact of Headache in Europe: a review for the Eurolight Project. *J Headache Pain* 2008; June: 9(3): 139-46.
8. Ponka D., Kirlaw M. Top 10 Differential Diagnosis in Family Medicine: Vertigo and Dizziness. *Can Fam Physician* 2007; Nov: 53(11):1959.
9. Tuchin P., Brooks M., Swaffer T. A Case Study of Chronic Headache. *Australas Chiropr Osteopathy* 1996; July: 5(2): 47-52.
10. Kessinger R., Boneva D. Vertigo, Tinnitus, and Hearing Loss in the Geriatric Patient. *J Manipulative Physiol Ther* 2000; June: 23(5): 352-62.
11. Barrett K., Ward A., Boughey A., Jones M., Mychalkiw W. Sequelae of Minor Head Injury: The Natural History of Post-Concussive Symptoms and Their Relationship to Loss of Consciousness and Follow Up. *J Accid Emerg Med* 1994;11:79-84.
12. Sweat R, editor. Atlas Orthogonal Chiropractic Program. 6th Ed. Atlanta (GA); 2007. p. 14-232
13. Takele G., Haimanot R., Martelletti P. Prevalence and Burden of Primary Headaches in Akaki Textile Mill Workers, Ethiopia. *J Headache Pain* 2008; April:9(2): 119-128.
14. Swartz R., Longwell P. Treatment of Vertigo. *Am Fam Physicians* 2005; March: 71 (6): 1115-1122
15. Wilhelmsen K, Ljunggran A, Goplen F, Eide G, Nordahl S. Long-term Symptoms in Dizzy Patients Examined in a University Clinic. *BMC Ear Nose Throat Disord* 2009: 9(2).
16. Demetrious J. Post-traumatic Upper Cervical Subluxation Visualized by MRI: a Case Report. *Chiropr Osteopat* 2007; 15:20.

Figures

Figure 1: Example of Pre and Post Supine Leg Length Analysis

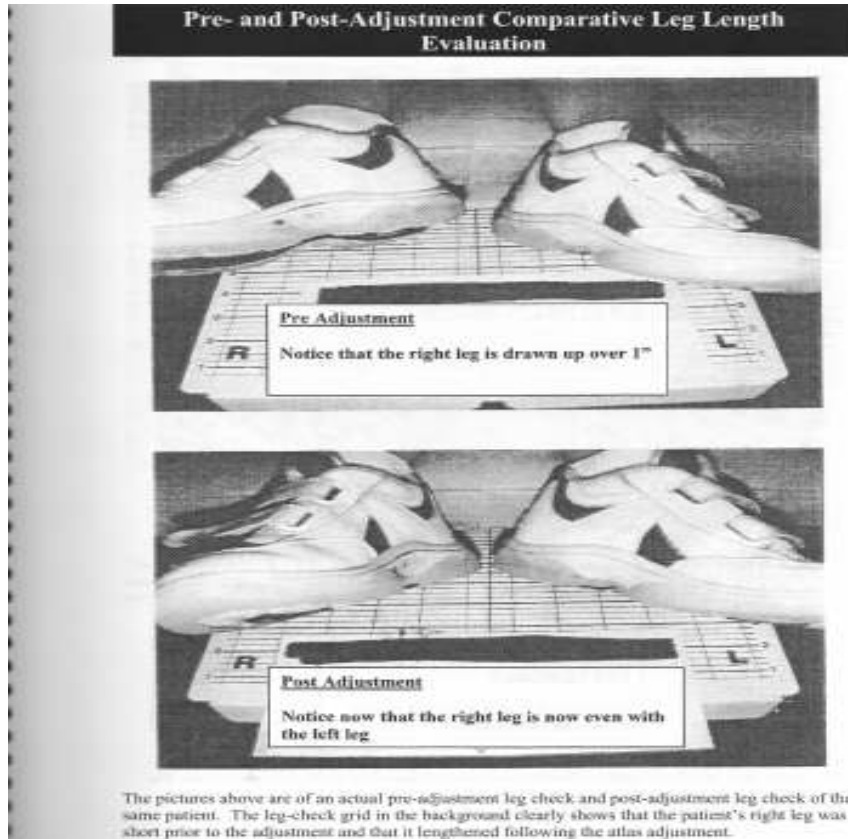


Figure 2: Example of Atlas Sagittal Plane Line, ASP lines correlation to facial features

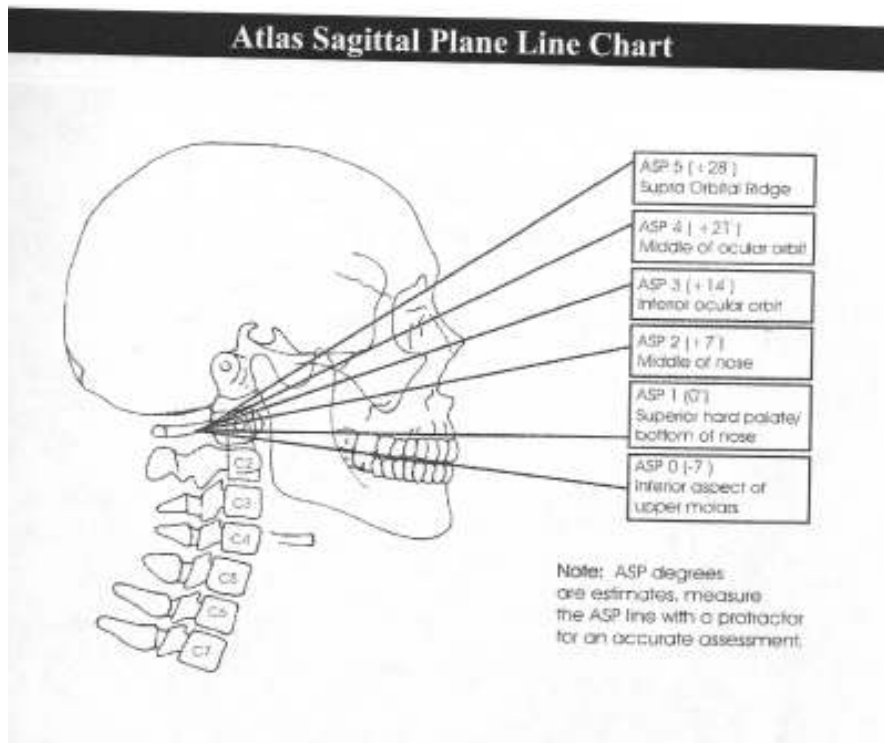


Figure 3: The Patient's Pre Adjustment Frontal X-Ray

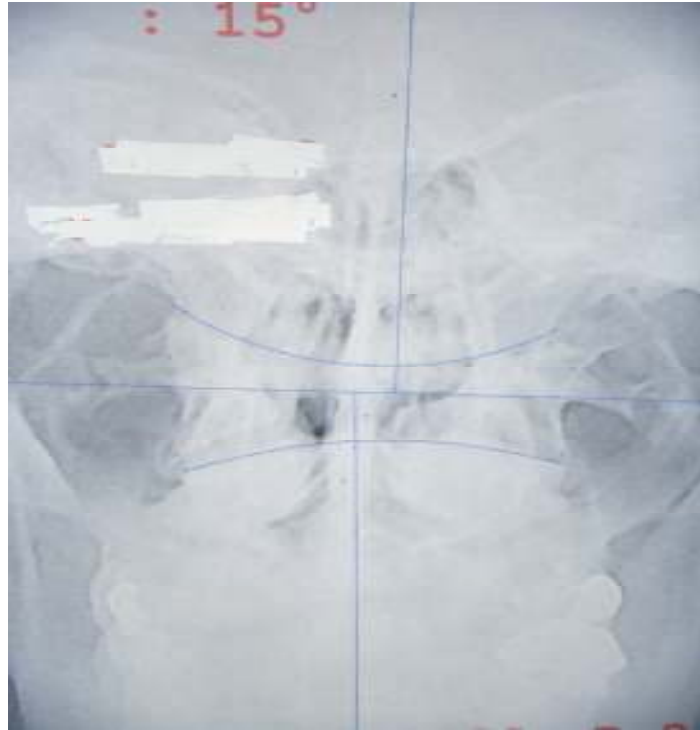


Figure 4: The patient's post adjustment Frontal X-Ray

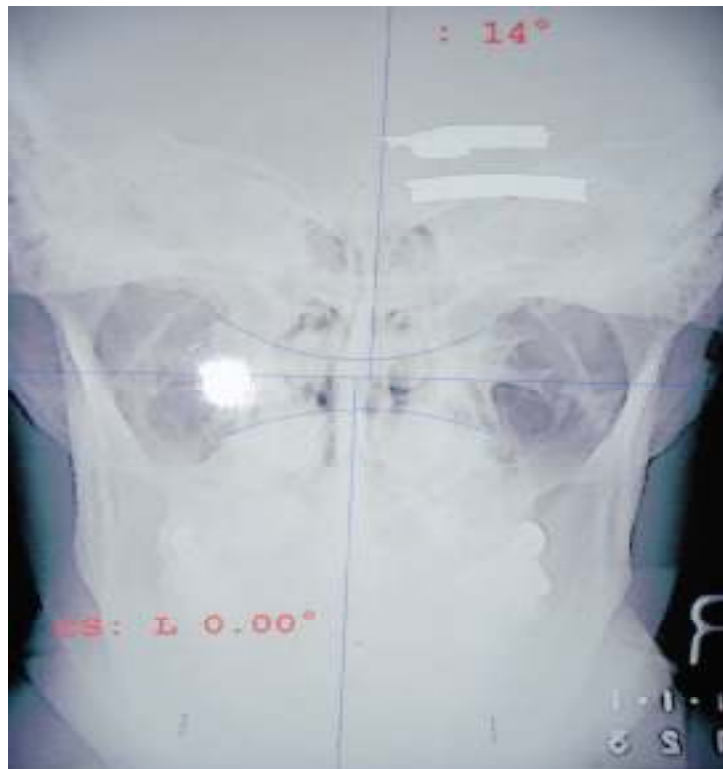

Table 1: Summary of Radiographic Findings

Radiographic Findings		
<i>View</i>	<i>Pre Adjustment Analysis</i>	<i>Post Adjustment Analysis</i>
Sagittal	ASP 2 (+15)	ASP 2 (+13)
Frontal	AFP high 3 degrees CS right 3.25 degrees ACD left 1.25 degrees CS right 3.25 degrees C/A of 8 degrees AXSP left 9 degrees	AFP 0 degrees CS 0 degrees ACD right 0.75 degrees CS 0 degrees C/A of 13 degrees AXSP left 4 degrees
Horizontal	AHRy anterior 0.25 degrees	AHRy anterior 0.15 degrees
ASP= Atlas Sagittal Plane; AFP= Frontal Plane; CS= Cervical Spine; ACD= Atlas Cephalic Displacement; C/A= Circle Tangent Angle; AXSP= axis spinous rotation; AHRy= Atlas Horizontal Rotation		